

24. Tadamura E, Tamaki N, Yonekura Y, et al. Assessment of coronary vasodilator reserve by N-13 ammonia PET using the microsphere method and Patlak plot analysis. *Ann Nucl Med* 1995;9:109-118.
25. Tadamura E, Tamaki N, Okazawa H, et al. Generator-produced copper-62-PTSM as a myocardial PET perfusion tracer compared with nitrogen-13-ammonia. *J Nucl Med* 1996;37:729-735.
26. Tamaki N, Magata Y, Takahashi N, et al. Oxidative metabolism in the myocardium in normal subjects during dobutamine infusion. *Eur J Nucl Med* 1993;20:231-237.
27. Gropler RJ, Siegel BA, Geltman EM. Myocardial uptake of carbon-11-acetate as an indirect estimate of regional myocardial blood flow. *J Nucl Med* 1991;31:245-251.
28. Brown M, Marshall DR, Sobel BE, Bergmann SR. Delineation of myocardial utilization with carbon-11-labeled acetate. *Circulation* 1987;76:687-696.
29. Ambrecht JJ, Buxton DB, Brunken RC, Phelps ME, Schelbert HR. Regional myocardial oxygen consumption determined non-invasively in humans with [¹¹C] acetate and dynamic positron tomography. *Circulation* 1989;80:863-872.
30. Hata T, Nohara R, Fujita M, et al. Noninvasive assessment of myocardial viability by positron emission tomography with ¹¹C acetate in patients with old myocardial infarction. Usefulness of low-dose dobutamine infusion. *Circulation* 1996;94:1834-1841.
31. Hoffman EJ, Huang SC, Phelps ME. Quantitation in positron computed tomography: 1. Effect of object size. *J Comput Assist Tomogr* 1979;3:299-308.
32. Knapp FF Jr, Ambrose KR, Goodman MM. New radioiodinated methyl-branched fatty acids for cardiac studies. *Eur J Nucl Med* 1986;12:S39-S44.
33. Tamaki N, Kawamoto M, Yonekura Y, et al. Regional metabolic abnormality in relation to perfusion and wall motion in patients with myocardial infarction: assessment with emission tomography using an iodinated branched fatty acid. *J Nucl Med* 1992;33:659-667.
34. Fujibayashi Y, Yonekura Y, Takemura Y, et al. Myocardial accumulation of iodinated beta-methyl-branched fatty acid analogue, iodine-125-15-(p-iodophenyl)-3-(R,S) methyl pentadecanoic acid (BMIPP), in relation to ATP content. *J Nucl Med* 1990;31:1818-1822.
35. Fujibayashi Y, Som P, Yonekura Y, et al. Myocardial accumulation of iodinated beta-methyl-branched fatty acid analogue, iodine-125-15-(p-iodophenyl)-3-(R,S) methyl pentadecanoic acid (BMIPP), and correlation to ATP concentration II. Studies in salt-induced hypertensive rats. *Nucl Med Biol* 1992;2:62-66.
36. Kawamoto, M, Tamaki, N, Yonekura, Y, et al. Significance of myocardial uptake of iodine-123-labeled beta-methyl iodophenyl pentadecanoic acid: comparison with kinetics of carbon-11-labeled palmitate in positron emission tomography. *J Nucl Cardiol* 1994;1:522-528.
37. Kelly DP, Strauss AW. Inherited cardiomyopathies. *N Engl J Med* 1994;330:913-919.
38. Tein I, De Vivo DC, Bierman F, et al. Impaired skin fibroblast carnitine uptake in primary systemic carnitine deficiency manifested by childhood carnitine-responsive cardiomyopathy. *Pediatr Res* 1990;28:247-255.
39. Stanley CA, Hale DE, Berry GT, Deleuw S, Boxer J, Bonnefont J-P. A deficiency of carnitine-acylcarnitine translocase in the inner mitochondrial membrane. *N Engl J Med* 1992;327:19-23.
40. Hug G, Bove KE, Soukup S. Lethal neonatal multiorgan deficiency of carnitine palmitoyltransferase II. *N Engl J Med* 1991;325:1862-1864.
41. Taroni F, Vederio E, Fiorucci S, et al. Molecular characterization of inherited carnitine palmitoyltransferase II deficiency. *Proc Natl Acad Sci USA* 1992;89:8429-8433.
42. Hale DE, Batshaw ML, Coates PM, et al. Long-chain acyl coenzyme A dehydrogenase deficiency: an inherited cause of nonketotic hypoglycemia. *Pediatr Res* 1985;19:666-671.
43. Rocchiccioli F, Wanders JJA, Aubourg P, et al. Deficiency of long-chain 3-hydroxyacyl-CoA dehydrogenase deficiency: a cause of lethal myopathy and cardiomyopathy in early childhood. *Pediatr Res* 1990;28:657-662.
44. Kusaka Y, Tanaka T, Okamoto F, et al. Effect of sulfo-N-succinimidyl palmitate on the rat heart: myocardial long-chain fatty acid uptake and cardiac hypertrophy. *J Mol Cell Cardiol* 1995;27:1605-1612.
45. Iida H, Kanno I, Takahashi A, et al. Measurement of absolute myocardial blood flow with H₂¹⁵O and dynamic positron emission tomography. Strategy for quantification in relation to the partial-volume effect. *Circulation* 1988;78:104-115.
46. Bergmann SR, Weinheimer CJ, Markham J, Herrero P. Quantification of myocardial fatty acid metabolism using PET. *J Nucl Med* 1996;37:1723-1730.
47. Iida H, Rhodes CG, Araujo LI, et al. Noninvasive quantification of regional myocardial metabolic rate for oxygen by use of ¹⁵O₂ inhalation and positron emission tomography. Theory, error analysis, and application in humans. *Circulation* 1996;94:792-807.

Perfusion-Contraction Mismatch During Inotropic Stimulation in Hibernating Myocardium

Gianmario Sambucetti, Assuero Giorgetti, Luca Corsiglia, Cecilia Marini, Jan Schneider-Eicke, Claudio Brunelli,

Paolo Marzullo, Antonio L'Abbate, Salvatore Capponnetto and Oberdan Parodi

Consiglio Nazionale delle Ricerche Institute of Clinical Physiology, Pisa; and Cattedra di Cardiologia, University of Genoa, Genoa, Italy

The aims of this study were to assess the value of dobutamine echocardiography in identifying myocardial hibernation versus stunning and to elucidate the underlying pathophysiological mechanism of the contractile impairment. **Methods:** Twenty-one patients with isolated stenosis of the left anterior descending artery were evaluated 1 mo after thrombolysed acute anterior infarction. Regional function and blood flow were measured using echocardiography and PET at rest and during dobutamine administration (10 µg/kg/min). **Results:** Defined by [¹⁸F]fluorodeoxyglucose uptake, 36 of 102 dyssynergic segments were necrotic, and 66 were viable. The latter segments were subdivided according to their [¹³N]ammonia flow distribution: 30 hibernating regions with perfusion defects (flow of <80% of maximum) and 36 stunned areas with preserved resting perfusion (flow of ≥80% of maximum). Resting flows were similar in necrosis and hibernation (0.43 ± 0.18 versus 0.47 ± 0.16 ml·min⁻¹·g⁻¹; not significant), and both resting values were lower than those seen in stunning (0.79 ± 0.24; p < 0.05). Flow response to dobutamine was markedly reduced in necrosis (dobutamine/resting flow = 1.16 ± 0.27), whereas it was maintained in hibernation (1.65 ± 0.54) and stunning (1.42 ± 0.57). Dobutamine improved function in a higher number of stunned (55%) than hibernating (16%) or necrotic (11%) segments. **Conclusion:** Dobutamine improves

function mainly in stunned myocardium and does not reliably identify hibernation. The lack of functional response in hibernation is not related to an exhausted vasodilating capacity.

Key Words: PET; echocardiography; myocardial blood flow; myocardial infarction

J Nucl Med 1998; 39:396-402

After thrombolysis for acute myocardial infarction, a residual dysfunction can be observed in the majority of cases. In these patients, the appropriate choice of either conservative or interventional therapy depends on the correct identification of the mechanisms underlying the contractile impairment.

Postinfarction left ventricular dysfunction can arise from myocardial hibernation (1), stunning (2) or necrosis. Myocardial hibernation is defined as chronic wall motion abnormality associated with resting hypoperfusion. Stunning represents a prolonged posts ischemic dysfunction despite the restoration of a normal or near normal blood flow. In stunning and necrosis, no further interventions are necessary. In the first case, function will recover spontaneously, and the second case represents irreversible damage.

In contrast, the recognition of myocardial hibernation is particularly relevant because it indicates the need for revascu-

Received Jan. 16, 1997; revision accepted May 8, 1997.

For correspondence or reprints contact: Oberdan Parodi, MD, Consiglio Nazionale delle Ricerche Institute of Clinical Physiology, Via P. Savi, 8 I-56100, Pisa, Italy.

larization to improve not only left ventricular function but also prognosis (3–5). To identify myocardial viability in hypoperfused myocardium, several tests have been proposed, such as the preservation of sarcolemmal integrity, as identified by ^{201}Tl scintigraphy (6), or the preservation of glucose metabolism, as evaluated by PET (3–5).

Dobutamine echocardiography has been proposed as a method to identify residual viability in chronically dyssynergic areas (7–11). However, several studies suggested that this method might not reliably detect hibernating segments (12, 13). To explain this finding, the authors speculated that the lack of contractile response to dobutamine stimulation might reflect induced ischemia due to an exhausted vasodilator reserve in regions with resting hypoperfusion.

This point is of crucial relevance. According to this hypothesis, a negative dobutamine echocardiography would not allow differentiation between necrotic areas and viable segments in inducible ischemia. If these patients were assessed correctly, revascularization would offer them the double benefit of improving resting left ventricular function as well as prevention of the occurrence of stress-induced ischemia. In discordance with this hypothesis, previous studies have consistently reported a residual vasodilator reserve in chronically hypoperfused dysfunctional viable myocardium (14–16).

The aim of this study was to assess the value of dobutamine echocardiography to correctly detect myocardial hibernation, as identified by PET. Additionally, regional flow response to dobutamine was evaluated to verify whether the described lack of contractile response to dobutamine is related to an exhausted vasodilator reserve.

MATERIALS AND METHODS

The study group consisted of 21 consecutive patients (17 men and 4 women; mean age = 58 ± 7 yr) with first acute anterior myocardial infarction that was treated by intravenous thrombolysis within the first 6 hr of the onset of symptoms. The anterior infarction was diagnosed on the basis of typical chest pain, acute ST-T wave changes and the subsequent appearance of Q waves. Peak serum enzyme concentration was 2575 ± 1068 units.

Inclusion criteria were:

1. Single-vessel disease of the left anterior descending coronary artery;
2. Postinfarction period free from heart failure, anginal symptoms or life-threatening arrhythmias;
3. PredischARGE Holter monitoring negative for ST-T segment changes; and
4. Negative submaximal bicycle exercise stress test (25-W steps every 2 min) performed 30 days after an acute event (average maximum rate pressure product = $21,887 \pm 6666$ mmHg·bpm).

Exclusion criteria were:

1. Unstable angina;
2. Arterial hypertension;
3. Left ventricular hypertrophy;
4. Valvular heart disease or other detectable cardiac disorders; or
5. Diabetes mellitus.

All patients agreed to participate in the study after being informed of the partially investigative nature of the protocol, which was approved by the local Ethics Committee on Human Studies.

Coronary Angiography and Left Ventriculography

Standard coronary angiography in multiple views was performed within 20 days after thrombolysis. All angiograms were evaluated

by two independent observers who identified stenotic segments and scored control arteries as either smooth or irregular. All angiograms were evaluated by an automated edge detection system (Mipron, Kontron, Germany), providing the percentage cross-sectional area reduction of coronary stenosis ($84\% \pm 12\%$). Patients with $>25\%$ area reduction in any of the remaining coronary arteries were excluded. Biplane left ventriculography was performed in all patients. Ejection fraction was calculated according to the area-length method (0.53 ± 0.17).

Study Protocol

Dobutamine echocardiography was performed 24 ± 3 days after thrombolysis. No patient was under inotropic drugs before the test, and beta-blockers were discontinued ≥ 96 hr before the study. Concomitant medications (nitrates, angiotensin-converting enzyme inhibitors and aspirin) were not withdrawn.

A commercially available wide-angle phased-array imaging system and a 2.5-MHz transducer were used. Images were acquired in standard views and recorded on videotape for off-line analysis. A two-dimensional echocardiogram was recorded at rest. Dobutamine infusion was performed at 5 and 10 $\mu\text{g}/\text{kg}/\text{min}$ using an intravenous infusion pump, with each step lasting 5 min. A three-lead electrocardiogram (ECG) was continuously monitored, whereas complete ECG and blood pressure were recorded at baseline and at every minute during the test. During the last 3 min of the infusion, classic echocardiographic views were obtained.

Wall motion in all segments was assessed visually by two observers unaware of the clinical, tomographic and angiographic data; discrepancies were resolved by consensus. The following scoring system was used: normal wall motion, hypokinesis (severely reduced systolic thickening and inward motion) and akinesis (absent systolic thickening and motion). In no case was dyskinesis observed. Improvement of contractile function during dobutamine infusion was diagnosed when systolic myocardial thickening either became apparent in an akinetic segment or normalized in a hypokinetic segment.

A PET study was performed in a two-day protocol within 2 wk from the echocardiographic study (39 ± 9 days after thrombolysis). After an overnight fasting period, all patients underwent oral glucose loading (50 g) and were positioned on the bed of a two-ring positron emission tomograph (ECAT III; CTI Inc., Knoxville, TN) providing three simultaneous cross-sectional planes. Standard transmission images were acquired to generate attenuation correction factors. Correct positioning was maintained throughout the study by use of a light beam and indelible marks on the torso. Fluorine-18-fluorodeoxyglucose was injected intravenously (7–10 mCi), and a 60-min period was allowed for myocardial uptake before acquisition of a static 10-min myocardial image.

The next day, patients underwent a new transmission scan in the same position as the day before, identified by the felt-tip pen marks on the torso. Nitrogen-13-ammonia was administered at a dose of 0.2 mCi/kg of body weight over a 10- to 20-sec period. Twenty-eight dynamic frames were acquired over 8 min (16 frames for 3 sec, 11 frames for 12 sec and 1 frame for 300 sec).

Fifty minutes after the baseline study, dobutamine was administered in accordance with the echocardiographic protocol. The dynamic [^{13}N]ammonia scan was started 3 min after the beginning of the 10 $\mu\text{g}/\text{kg}/\text{min}$ dobutamine dosage. Two minutes later (1 min before acquisition of the last frame), the infusion was stopped.

A three-lead ECG was continuously monitored, whereas a nine-lead ECG and arterial blood pressure were obtained during [^{13}N]ammonia injection at rest as well as every minute during dobutamine infusion.

Positron emission tomography

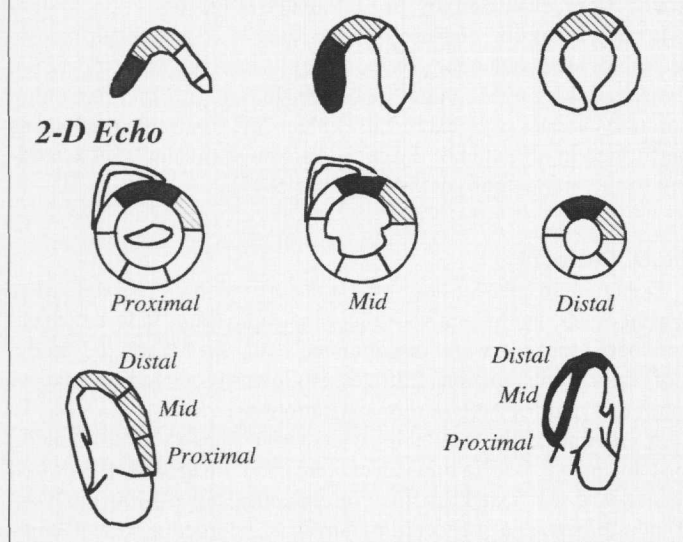


FIGURE 1. Schematic representation of the myocardial segments used for comparison of two-dimensional echocardiography and PET. The basal, mid and distal apical tomographic planes are shown for both techniques. Apical two-chamber (bottom left) and apical four-chamber (bottom right) echocardiographic views are also presented. Dotted, dashed and open areas represent septal, anterior and postero-lateral regions, respectively. Due to the technical characteristics of our tomograph, inferior segments were not analyzed.

Blood Flow Analysis

Myocardial blood flow (MBF) was calculated according to a previously validated method (17). Briefly, only the transversal plane visualizing the left ventricle at its best was analyzed. Into each of the three walls, i.e., septal, anterior and postero-lateral, three small regions of interest (ROI) (25–30 voxels) were drawn to calculate regional ammonia uptake, resulting in a total of 189 regions in the 21 patients. The time curve of [¹³N]ammonia activity in the arterial blood was computed, with a small ROI placed in the left ventricular cavity.

Regional MBF times [¹³N]ammonia extraction (rMBFe) was calculated as:

$$MBFe = C_m \times 60 \int_0^{\infty} C_b(t) \times dt, \quad \text{Eq. 1}$$

where C_m and C_b are [¹³N]ammonia activity concentrations in the myocardium in the last frame and in the arterial blood at each time t , respectively. The $C_b(t)$ curve was fitted by a gamma variate function for integration. The rMBFe values were then divided by tissue gravity (1.08 g/ml) to obtain the real values in $\text{ml} \cdot \text{min}^{-1} \cdot \text{g}^{-1}$. Actual regional MBF values were calculated from rMBFe by using the experimental relationship between ammonia uptake and microsphere-determined flow observed in animal preparations (17):

$$\text{Regional MBF} = \exp[(rMBFe + 0.04)/1.45] - 1. \quad \text{Eq. 2}$$

Segment Classification

Due to the technical characteristics of our tomograph, it was only possible to analyze regional perfusion and metabolism in the septal, anteroapical and postero-lateral walls (Fig. 1). To compare the echo data with PET findings, regional wall motion analysis was performed by correspondingly dividing postero-lateral, anteroapical and septal walls into three segments, thus resulting in 189 matching echocardiographic regions.

To identify resting hypoperfusion, regional values were expressed as percentages of the maximum flow value of each patient.

TABLE 1
Hemodynamic Data During Echocardiographic Study and PET Study

	Heart rate (bpm)	Systolic arterial pressure (mmHg)	Rate-pressure product (mmHg · bpm)
Echocardiographic study			
Baseline	65 ± 18	119 ± 18	7194 ± 1755
Dobutamine	80 ± 18*	138 ± 21*	9763 ± 3243*
PET			
Baseline	63 ± 13†	124 ± 16†	7273 ± 1996†
Dobutamine	76 ± 14*†	143 ± 29*†	10225 ± 2765*†

* $p < 0.05$ vs. corresponding baseline.

†Not significant vs. corresponding condition of echocardiographic study.

Data for regional glucose uptake were also normalized. The glucose uptake of the region showing maximum baseline blood flow served as the 100% reference value. Flow values <80% of the maximum (18) represented hypoperfusion. These hypoperfused regions were considered necrotic in the presence of a concordant reduction in perfusion and deoxyglucose uptake (i.e., flow of <80% of the maximum and a percentage deoxyglucose activity/percentage perfusion of ≤ 1.2). Hypoperfused segments were considered hibernating in the presence of a classic mismatch pattern (i.e., flow of <80% of the maximum and percentage deoxyglucose activity/percentage perfusion of > 1.2) (12,19,20). Stunned myocardium was identified by regional dysfunction in segments with normal perfusion and glucose uptake.

Statistical Analysis

All data are expressed as mean values ± s.d. Analysis of variance, followed by Newman-Keuls procedure for multiple comparisons, was used to compare flow values between groups at baseline and during dobutamine administration. Student's t-test was used to compare flow values at baseline and during dobutamine administration in each group. The chi-square test was applied to evaluate differences in the rates of occurrence. Linear regression analysis was performed by the least squares method. A probability (p) value of <0.05 was considered significant.

RESULTS

Clinical and Hemodynamic Findings

Dobutamine infusion was well tolerated in all cases, and no patient had serious side effects as a result of the study. As shown in Table 1, baseline and dobutamine rate pressure products were comparable during echocardiographic and tomographic acquisition. Dobutamine administration increased the rate pressure product moderately but significantly. No patient developed diagnostic ST-T segment changes or complained of chest pain during either dobutamine echocardiography or PET study.

Wall Motion Data

All 63 regions assigned to the postero-lateral wall remote to infarction showed normal function. Of 126 regions supplied by the left anterior descending coronary artery, 24 showed normal wall motion, 42 showed hypokinesis and 60 showed akinesis.

Considering all dyssynergic segments, dobutamine improved function in 30 of 102 (29%) regions. A positive response to inotropic stimulation was observed in 18 of 42 (43%) hypokinetic and 12 of 60 (20%) akinetic segments ($p < 0.05$). Irrespective of baseline function, deterioration of wall motion was never observed in any segment at 5 or 10 $\mu\text{g}/\text{kg}/\text{min}$ dobutamine infusion. Thus, in asymptomatic patients evaluated

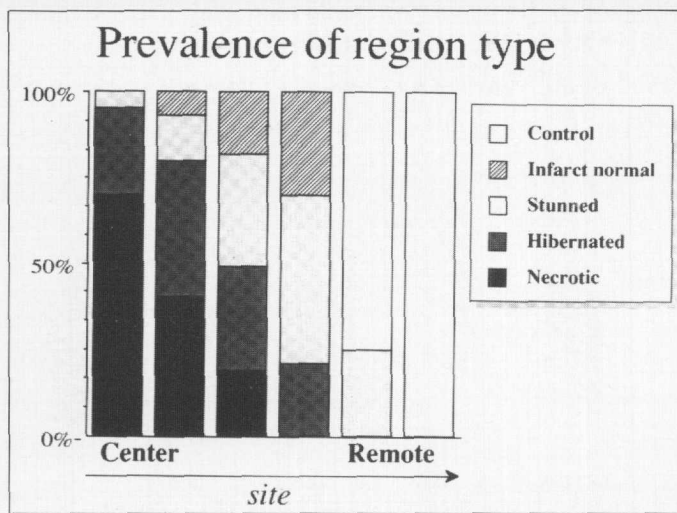


FIGURE 2. Prevalences of region type according to the distance from the core of infarction. The prevalences of necrotic and hibernating regions decrease toward the periphery of infarction. Stunned segments shows the highest prevalence between these regions and those with normal wall motion.

1 mo after thrombolysed uncomplicated anterior myocardial infarction, the prevalence of dysfunctional but viable myocardium identified by dobutamine echocardiography was relatively low.

Relationships Between Resting Blood Flow, Metabolism and Regional Function

Of a total of 189 regions, five groups were defined according to anatomical and functional characteristics. All 63 posterolateral regions showed normal resting perfusion, glucose uptake and wall motion. Because these regions were supplied by the angiographically normal left circumflex artery, they served as control regions. Among the remaining 126 segments supplied by the left anterior descending artery, 24 were normal as well. Of the 102 regions identified at echocardiography as being dyssynergic, 36 showed normal perfusion and metabolism and were considered stunned. Furthermore, 30 segments displayed regional hypoperfusion in the presence of a maintained glucose uptake and were regarded as hibernating. The remaining 36 regions showed a concordant reduction of perfusion and metabolism and were, therefore, considered necrotic.

A necrotic pattern was present in 9 of 42 (21%) hypokinetic and 27 of 60 (45%) akinetic regions ($p < 0.01$), whereas it was never observed in segments with normal wall motion. Baseline wall motion analysis showed a larger prevalence of hypokinesis in stunned (22 of 36, or 61%) than in hibernating (11 of 30, or 37%) areas ($p < 0.05$).

The prevalences of necrotic, stunned and hibernating regions showed a large interpatient variability (average values were $46\% \pm 35\%$, $31\% \pm 31\%$ and $23\% \pm 26\%$, respectively). In four patients, no necrosis was observed, whereas hibernation was absent in seven patients. Necrotic segments prevailed in the core of infarction and tended to decrease toward the periphery; hibernating regions behaved similarly. In contrast, stunned areas were found more frequently in the border zone between normal and hypoperfused segments (Fig. 2).

Average flow data are summarized in Table 2. Stunned segments showed resting flow values similar to those observed in control areas and normal segments supplied by the left anterior descending coronary artery (Fig. 3). Among hypoperfused areas, the presence of residual viability (identified by deoxyglucose uptake) was not associated with the degree of

resting flow impairment. In fact, hibernating and necrotic areas showed superimposable values of baseline blood flow. Remarkably, flow increase during dobutamine was still present in hibernating segments demonstrating a residual vascular tone despite resting hypoperfusion. Additionally, flow response was small but significant in necrotic areas (Fig. 3).

A contractile response to dobutamine was observed more frequently in stunned (Fig. 4) than in hibernating (Fig. 5) or necrotic (Fig. 6) regions (23 of 42, or 55%; 5 of 31, or 16%; and 4 of 36, or 11%, respectively; $p < 0.01$) (Fig. 7). Furthermore, the number of dyssynergic segments that improved function during dobutamine administration in each patient significantly correlated ($r = 0.56$; $p < 0.05$) with the corresponding number of stunned segments but not with the number of either hibernating or necrotic segments ($r = 0.14$ and 0.24 , respectively; not significant).

DISCUSSION

The results of this study indicate that, 1 mo after thrombolysis for acute myocardial infarction, stunned and hibernating myocardium respond differently to inotropic stimulation. In the majority of stunned regions, dobutamine improved wall motion, whereas in a large number of hibernating areas, no contractile response could be observed. Despite this variance in regional contractility, the flow response to dobutamine was remarkably similar in both models of resting dysfunction. This perfusion-contraction mismatch in hibernating myocardium suggests that the limited contractile response to inotropic stimulation is not caused by ischemia.

Mechanisms Underlying Postinfarction Resting Dysfunction

This study confirms that postinfarction wall motion abnormality can be observed in viable myocardium with either preserved or reduced resting perfusion. The association of normal blood flow with persistent dysfunction might reflect the presence of myocardial stunning (2). By contrast, the finding of resting hypoperfusion and dysfunction might indicate either myocardial hibernation (1) or a mixture of scar and viable tissue (21). In this latter case, the presence of poorly perfused fibrotic tissue might have led to an underestimation of regional specific flow to the residual normoperfused viable myocardium (21). Probably the hibernating nature of hypoperfused segments would have been more clearly demonstrated by the measurement of reduced flow per unit mass of viable myocardium (21). However, it should be also considered (22,23) that a preserved glucose metabolism reliably identifies those hypoperfused areas showing recovery of flow and function after revascularization. Moreover, in this study, these hypoperfused viable segments showed the largest blood flow response to dobutamine; when compared with the blunted response of regions with necrotic pattern, this finding suggests the presence of chronic hypoperfusion of viable myocardium (16).

Inotropic Stimulation in Stunned Myocardium

The reliability of dobutamine echocardiography in predicting spontaneous functional recovery of stunned myocardium after acute myocardial infarction has already been well documented (7,12). This study partially confirms these previous observations by showing a contractile response in 55% of stunned segments. In comparison to these previous reports, the percentage of myocardium showing a functional improvement during dobutamine is smaller. This discrepancy probably reflects differences in study design. In our protocol, patients were examined 4 wk after myocardial infarction, whereas in previous studies, the test was performed shortly after thrombolysis.

Accordingly, this discrepancy suggests that regions that are still stunned 4 wk after myocardial infarction show a reduced sensitivity to dobutamine. However, it also indicates that, even after such a prolonged period, not all stunned regions had recovered. This finding is partially confirmed by the observation of a higher prevalence of hypokinesis in regions with stunned pattern, as compared with either hibernating or necrotic areas.

This study extends the comprehension of the pathophysiology underlying inotropic stimulation in stunned myocardium. It documents that the normalization of contractility induced by dobutamine is associated with an increased flow. Because an abnormal baseline function is observed despite the presence of a normal resting flow, this finding agrees with the hypothesis of a metabolic alteration as the cause of dysfunction in stunned myocardium in patients after acute myocardial infarction (2).

Inotropic Stimulation in Hibernating Myocardium

In the detection of hibernating myocardium, the value of dobutamine echocardiography is still controversial. Several studies reported promising results in identifying residual viability in chronically dysfunctioning segments (8-11). However, in these reports, the nature of the resting dysfunction was not precisely defined, and the relationship between wall motion abnormality and resting hypoperfusion was not investigated. Moreover, these studies evaluated patients undergoing revascularization for stress-induced ischemia and/or angina. In these anginal patients, regional dysfunction may rather reflect repetitive stunning then hibernation (24). Actually, several authors reported that hibernating myocardium, identified on the basis of PET, does not show a significant contractile response to dobutamine (12,13). To explain the lack of functional improvement, they hypothesized that the increased metabolic demand could not be matched by a parallel increase in blood flow. This hypothesis was based on the assumption that vasodilator reserve is exhausted in the presence of a severe stenosis and resting hypoperfusion.

This study confirms the observation that hibernating myocardium shows little functional response to dobutamine. However, the lack of contractile improvement does not seem to be caused by the occurrence of ischemia. In fact, no patient complained of chest pain or developed ST-T segment changes during the test. Additionally, no patient showed initial improvement followed by consecutive deterioration of wall motion, an ischemic behavior that occurs at higher doses of dobutamine (11). Furthermore, the exercise stress test was negative in all patients, even at rate-pressure products markedly higher than those observed during dobutamine. Finally, in hibernating segments, a marked flow increase could be observed during dobutamine infusion. This finding should not have been caused by a partial volume effect, which was related to the change in left ventricular volumes induced by the drug (25). In fact, despite similar

Blood flow response

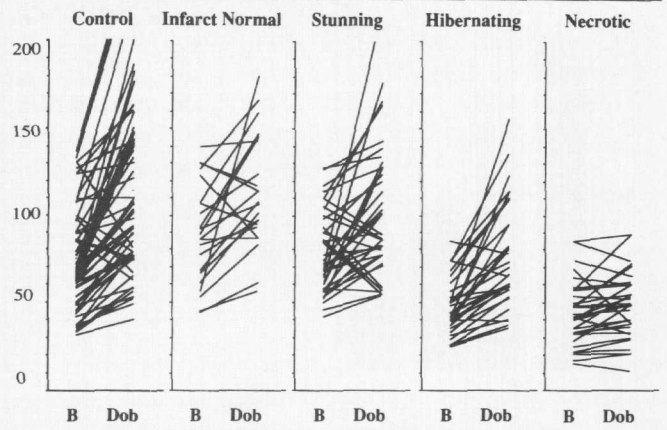


FIGURE 3. Individual flow values in the five groups of regions. A flow response to dobutamine was observed in all but necrotic segments. A large overlap in resting flow values was observed between necrotic and hibernating regions.

values of resting hypoperfusion, necrotic regions showed a blunted response to dobutamine, thus corroborating the concept of a vasodilator reserve in hibernating myocardium. This finding confirms previous observations by our group (14-16), showing that the vasodilator reserve is not exhausted even in those regions in which the chronic hypoperfusion is associated with contractile dysfunction.

In conclusion, the unresponsiveness of hibernating myocardium to inotropic stimulation does not seem to be related to the occurrence of ischemia. Alternative mechanisms might explain this observation. The reduced contractility might reflect ultrastructural or metabolic alterations of the myocardium, resulting in an exhausted contractile reserve (20). Furthermore, an abnormal transduction of the beta-1 stimulation (26,27) or a reduced activity of the stimulatory G_s proteins (27) could have reduced the sensitivity to dobutamine.

Study Limitations

The major limitation of this study is the lack of a follow-up evaluation of functional recovery after coronary revascularization. This limitation is primarily caused by the selection of

TABLE 2
Blood Flow Data (ml/min/g)

	No.	Rest	Dobutamine	Dobutamine/rest
Control	63	0.75 ± 0.29*†	1.14 ± 0.51*†	1.59 ± 0.50*
LAD normal WM	24	0.94 ± 0.27*†	1.23 ± 0.41*†	1.40 ± 0.50
Stunned	36	0.79 ± 0.23*†	1.04 ± 0.40*	1.39 ± 0.57
Hibernating	30	0.48 ± 0.16	0.78 ± 0.30*	1.66 ± 0.55*
Necrotic	36	0.43 ± 0.18	0.50 ± 0.24	1.16 ± 0.27

*p < 0.01 vs. necrotic segments.

†p < 0.01 vs. hibernating segments.

LAD = left anterior descending coronary artery; WM = wall motion.

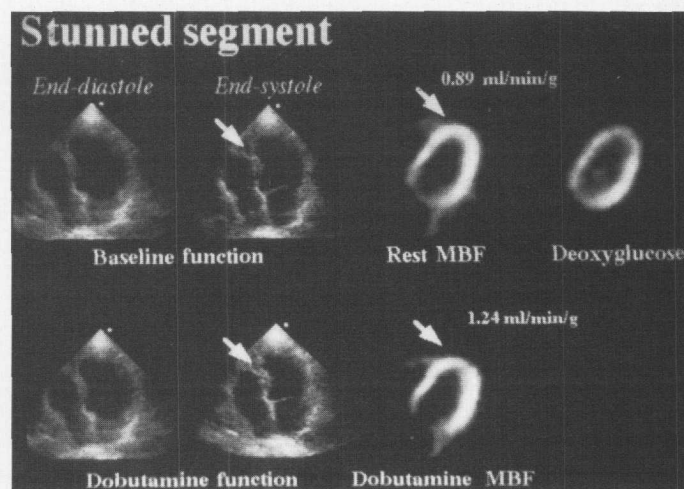


FIGURE 4. Echocardiographic and tomographic findings in myocardial stunning. The analysis of baseline wall motion (top left) shows septal akinesis improving during dobutamine administration (bottom left). PET study (right) revealed that the septal dysfunction was associated with a preserved perfusion (resting MBF) and deoxyglucose uptake raising the picture of stunned myocardium.

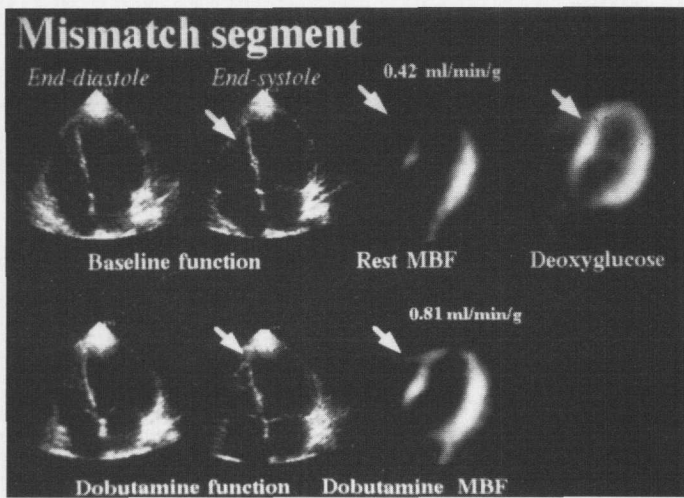


FIGURE 5. Echocardiographic and tomographic findings in myocardial hibernation. The analysis of baseline wall motion (top left) shows septal akinesia not improving during dobutamine (bottom left). PET study (right panels) revealed that the septal dysfunction was associated with a reduced perfusion (resting MBF) and preserved deoxyglucose uptake raising the picture of hibernating myocardium. Despite the lack of contractile response, dobutamine increased significantly regional MBF.

asymptomatic patients with first myocardial infarction. In these patients with preserved global left ventricular function and without evidence of stress-induced ischemia, the indication for percutaneous transluminal coronary angioplasty is still controversial (28). However, this selection permitted the study of both blood flow regulation and regional function in myocardial areas exposed to coronary occlusion and persistence of a severe stenosis, without the confounding effects of clinically evident ischemia.

A further limitation is represented by the lack of quantitative information about the regional metabolic rate of glucose. However, [^{18}F]fluorodeoxyglucose scans were performed to identify myocardial viability rather than to explore the regional relationship between blood flow and metabolism. In this setting, the additional value of quantitative estimates of glucose metabolism has not been established so far (29).

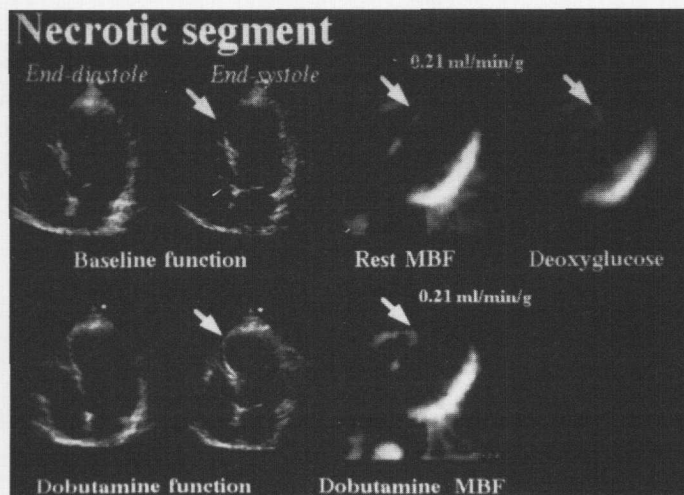


FIGURE 6. Echocardiographic and tomographic findings in myocardial necrosis. The analysis of baseline wall motion (top left) shows septal akinesia not improving during dobutamine (bottom left). PET study (right) revealed that the septal dysfunction was associated with an impaired perfusion (resting MBF) and deoxyglucose uptake raising the picture of necrosis. Dobutamine did not improve wall motion in this region and induced a limited effect on myocardial perfusion.

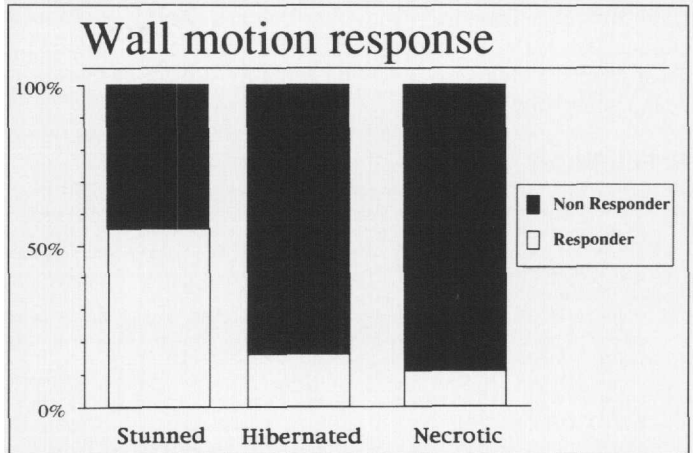


FIGURE 7. Effects of dobutamine on regional function according to baseline classification. Stunned regions (with preserved resting perfusion) shows a more evident functional response than did hibernating or necrotic areas.

Finally, for technical reasons, dobutamine echocardiography always preceded PET. This invariable sequence of testing might have introduced a systematic error because regional wall motion might have been changed at the time of flow measurement. This phenomenon might have occurred in some of the stunned regions. However, in chronically hypoperfused myocardium, an improvement in wall motion should be very unlikely in the absence of revascularization procedure. Moreover, in 10 of 21 patients, baseline echocardiography was repeated at the time of PET, and no changes were observed in regional and global left ventricular function.

CONCLUSION

The reliability of flow-metabolism mismatch in identifying viable myocardium has been recognized for a long time (16,19,20,22,23). Recently, dobutamine echocardiography has been shown to reliably identify those segments with chronic dysfunction that will recover after revascularization (8,10,11). In this study, we found that contractile response was present in a large number of stunned segments but not in the majority of regions classified as hibernating by flow-metabolism mismatch. This finding implies either an underestimation of echo in the recognition of myocardial hibernation or an overestimation of PET in the detection of reversible dysfunction.

Because blood flow response was preserved in hypoperfused viable segments, transient ischemia should not have been the cause of the unresponsiveness to dobutamine. Thus, this phenomenon might reflect more profound changes in the contractile properties of hibernating myocardium. In this line, myocardial viability and reversible dysfunction might not be synonymous. This hypothesis might explain the observation that a significant number of segments classified as hibernating by PET do not improve function after revascularization (20,23). This hypothesis needs to be confirmed by further prospective studies; however, it might indicate that, in patients with severely depressed left ventricular dysfunction, myocardial revascularization might improve prognosis (3–5) through a preservation of myocardial metabolism in hypoperfused areas, even in the absence a functional improvement.

ACKNOWLEDGMENTS

This study was presented in part at the 68th Annual Scientific Session of the American Heart Association, held November 12–16 1995, in Anaheim, California. This study was supported in part by the Consiglio Nazionale delle Ricerche—Targeted Project “Prevention and Control of Disease Factors,” Subproject “Control of

Cardiovascular Disease," from the National Research Council (Rome, Italy). Dr. J. Schneider-Eicke is a recipient of a training grant from the Human Capital and Mobility Project of the European Community.

REFERENCES

1. Rahimtoola SH. The hibernating myocardium. *Am Heart J* 1989;117:211-221.
2. Braunwald E, Kloner RA. The stunned myocardium. Prolonged posts ischemic ventricular dysfunction. *Circulation* 1982;66:1146-1149.
3. Eitzman D, Al Aouar Z, Kanter HL, et al. Clinical outcome of patients with advanced coronary artery disease after viability studies with positron emission tomography. *J Am Coll Cardiol* 1992;20:559-567.
4. DiCarli M, Davidson M, Little R, et al. Value of metabolic imaging with positron emission tomography for evaluating prognosis in patients with coronary artery disease and left ventricular dysfunction. *Am J Cardiol* 1994;73:527-533.
5. Lee KS, Marwick TH, Cook SA, et al. Prognosis of patients with left ventricular dysfunction, with and without viable myocardium after myocardial infarction. *Circulation* 1994;90:2687-2694.
6. Cuocolo A, Pace L, Ricciardelli B, Chiariello M, Trimarco B, Salvatore M. Identification of viable myocardium in patients with chronic coronary artery disease: comparison of thallium-201 scintigraphy with reinjection and technetium-99m-methoxyisobutyl isonitrite. *J Nucl Med* 1992;33:505-511.
7. Smart SC, Sawada S, Ryan T, et al. Low dose dobutamine echocardiography detects reversible dysfunction after thrombolytic therapy of acute myocardial infarction. *Circulation* 1993;88:405-415.
8. Marzullo P, Parodi O, Reichenhofer B, et al. Value of rest thallium-201/technetium-99m sestamibi scans and dobutamine echocardiography for detecting myocardial viability. *Am J Cardiol* 1993;71:166-172.
9. Cigarroa CG, de Filippi CR, Briker E, Alvarez LG, Wait MA, Grayburn PA. Dobutamine stress echocardiography identifies hibernating myocardium and predicts recovery of left ventricular function after coronary revascularization. *Circulation* 1993;88:430-436.
10. La Canna G, Alfieri O, Giubbini R, Gargano M, Ferrari R, Visioli O. Echocardiography during infusion of dobutamine for identification of reversible dysfunction in patients with chronic coronary artery disease. *J Am Coll Cardiol* 1994;23:617-626.
11. Afridi I, Kleiman NS, Raizner AF, Zoghbi WA. Dobutamine echocardiography in myocardial hibernation. *Circulation* 1995;91:663-670.
12. Pierard LA, de Landsheere CM, Berthe C, Rigo P, Kulbertus HE. Identification of viable myocardium by echocardiography during dobutamine infusion in patients with myocardial infarction after thrombolytic therapy: comparison with positron emission tomography. *J Am Coll Cardiol* 1990;15:1021-1031.
13. Elsnor G, Sawada S, Foltz J, et al. Dobutamine stimulation detects stunned but not hibernated myocardium [Abstract]. *Circulation* 1994;90:1-117.
14. Parodi O, Sambucetti G, Roghi A, et al. Residual coronary reserve despite decreased resting blood flow in patients with critical coronary lesions. A study by technetium-99m human albumin microsphere myocardial scintigraphy. *Circulation* 1993;87:330-344.
15. Sambucetti G, Parodi O, Marzullo P, et al. Regional myocardial blood flow in stable angina pectoris associated with isolated significant narrowing of either the left anterior descending or left circumflex coronary artery. *Am J Cardiol* 1993;72:990-994.
16. Marzullo P, Parodi O, Sambucetti G, et al. Residual coronary reserve identifies segmental viability in patients with wall motion abnormalities. *J Am Coll Cardiol* 1995;26:353-357.
17. Bellina CR, Parodi O, Camici P, et al. Simultaneous in vitro and in vivo validation of ^{13}N -ammonia for the assessment of regional myocardial blood flow. *J Nucl Med* 1990;31:1335-1343.
18. Sambucetti G, Marzullo P, Giorgetti A, et al. Global alteration in perfusion response to increasing oxygen consumption in patients with single vessel coronary artery disease. *Circulation* 1994;90:1696-1705.
19. Czernin J, Parenta G, Brunken R, et al. Regional blood flow, oxidative metabolism and glucose utilisation in patients with recent myocardial infarction. *Circulation* 1993;88:884-895.
20. Maes A, Flameng W, Nuyts J, et al. Histological alterations in chronically hypoperfused myocardium. *Circulation* 1994;90:735-745.
21. Marinho NVS, Keogh BE, Costa DC, Lammertma AA, Ell PJ, Camici PG. Pathophysiology of chronic left ventricular dysfunction. New insights from the measurement of absolute myocardial blood flow and glucose utilization. *Circulation* 1996;93:737-744.
22. Tillish JH, Brunken R, Marshall R, Schwaiger M, Mandelkern M. Reversibility of cardiac wall motion abnormalities predicted by positron emission tomography. *N Engl J Med* 1986;314:884-888.
23. Marwick TM, Cntyre WJ, Lafont A, Nemej J, Salcedo E. Metabolic response of hibernating and infarcted myocardium to revascularization: a follow up study of perfusion, function and metabolism. *Circulation* 1992;85:1347-1353.
24. Vanoverschelde JLI, Wijns W, Depré C, et al. Mechanisms of chronic regional posts ischemic dysfunction in humans. New insight for the study of noninfarcted collateral-dependent myocardium. *Circulation* 1993;87:1513-1523.
25. Gewirtz H, Grotte GJ, Strauss W, et al. The influence of left ventricular volume and wall motion on myocardial images. *Circulation* 1979;59:1172-1177.
26. Muntz KH, Olson EG, Lariviere GR, et al. Autoradiographic characterisation of beta adrenergic receptors in coronary blood vessels and myocytes in normal and ischemic myocardium of the canine heart. *J Clin Invest* 1984;73:349-357.
27. Susanni EE, Manders T, Knight DR, Vatner DE, Vatner SF, Homey CJ. One hour of myocardial ischemia decreases the activity of the stimulatory guanine-nucleotide regulatory protein Gs. *Circ Res* 1989;65:1145-1150.
28. Topol EJ, Ellis SG, Cosgrove DM, et al. Analysis of coronary angioplasty practice in the United States with an insurance claims data base. *Circulation* 1993;87:1489-1497.
29. Hariharan R, Bray M, Ganim R, Doenst T, Goodwin GW, Taegtmeyer H. Fundamental limitations of ^{18}F -2-deoxy-2-fluoro-D-glucose for assessing myocardial glucose uptake. *Circulation* 1995;91:2435-2444.

Quantitative Assessment of Transient Regional Ischemia During Rotational Atherectomy

Karl-Christian Koch, Eduard Kleinhaus, Heinrich G. Klues, Gernot Schulz, Martin Sigmund, Udalrich Buell, Peter Hanrath and Juergen vom Dahl

Departments of Internal Medicine I (Cardiology) and Nuclear Medicine, University Hospital, RWTH Aachen, Aachen, Germany

Sustained myocardial ischemia with angina pectoris, electrocardiographic changes and subsequent non-Q-wave infarctions has been reported during percutaneous transluminal rotational atherectomy of complex coronary lesions. The purpose of this study was to evaluate the effect of rotational atherectomy on regional myocardial perfusion as assessed by serial $^{99\text{mTc}}$ -sestamibi SPECT imaging with semiquantitative tracer uptake analysis. **Methods:** Twenty-nine consecutive patients with anginal symptoms, complex coronary lesions (all Type B and Type C) and preserved left ventricular function were studied using resting $^{99\text{mTc}}$ -sestamibi SPECT before rotational atherectomy, during and 2 days after the procedure. For semiquantitative computerized analysis, the left ventricular myocardium was divided into 24 regions, and regional perfusion was expressed as percentage of maximal sestamibi uptake. **Results:** Visual analysis of scintigraphic images revealed transient perfusion defects corresponding to the revascularized vessel in 26 of 29

patients, whereas three patients had no transient hypoperfusion. During rotational atherectomy, perfusion decreased significantly (>2 s.d. below normal mean) in 3.1 ± 2.4 regions (range 1-10). Perfusion in the territory of the revascularized vessel was $75\% \pm 11\%$ at baseline, decreased to $67\% \pm 12\%$ during rotational atherectomy ($p < 0.001$) and normalized again after rotational atherectomy to $78\% \pm 8\%$ ($p < 0.001$). Similarly, perfusion in the region with the maximal reduction decreased from $74\% \pm 15\%$ at baseline to $55\% \pm 14\%$ ($p < 0.001$) during the procedure and returned to $74\% \pm 16\%$ ($p < 0.001$) following the intervention. In calcified stenoses, the extent of perfusion defects was larger as compared to noncalcified (4.2 ± 2.5 versus 2.3 ± 2.0 regions/patient, $p < 0.05$). **Conclusion:** During rotational atherectomy, myocardial hypoperfusion occurs. The transient nature of this perfusion defect can be demonstrated and quantified by serial $^{99\text{mTc}}$ SPECT. This model may prove useful to assess the effects of pharmacological approaches to reducing myocardial hypoperfusion during coronary rotational atherectomy.

Key Words: coronary artery disease; myocardial perfusion; rotational atherectomy; SPECT; technetium-99m-sestamibi

J Nucl Med 1998; 39:402-408

Received Jan. 27, 1997; revision accepted May 6, 1997.

For correspondence or reprints contact: Juergen vom Dahl, MD, Medizinische Klinik I, Universitätsklinikum der RWTH Aachen, Pauwelstrasse 30, D-52057 Aachen, Germany.